

## PROCEDURAL DERMATOLOGY

## A survey of patient satisfaction with use of microwave device for axillary hyperhidrosis

Salvatore Scuderi,<sup>1</sup> Patricia Manoharan,<sup>2</sup> Davin Lim<sup>5</sup> and Shobhan Manoharan<sup>5</sup><sup>1</sup>Princess Alexander Hospital, <sup>2</sup>Brisbane Skin, and <sup>5</sup>Westside Dermatology, Brisbane, Queensland, Australia

## INTRODUCTION

Axillary hyperhidrosis is a common and socially disabling problem. It is known to have a severe impact on relationships, leisure activities, emotional well-being, work, productivity and self-esteem.<sup>1</sup> Many options are available for treatment, including topical and injectable agents, systemic drugs and surgical intervention. Apart from invasive surgery, most methods of treatment are only temporary and the patient is often left anxious as to when the sweating problem will return. Oral anticholinergics have significant side-effects including dryness of eyes and mouth, loss of bladder control and constipation.<sup>2</sup> Botulinum toxin type A injections have been successfully used to treat axillary hyperhidrosis but the effect is limited to 6 months.<sup>2</sup> Thus, it is only a temporary measure with significant costs and time involved. The use of a microwave device for the long-term treatment of axillary hyperhidrosis was introduced by Johnson and colleagues.<sup>5</sup> Microwaves cause the rotation of dipole molecules such as water, leading to the generation of significant heat.<sup>2</sup> The skin is cooled so that heating preferentially occurs at the interface with the s.c. fat, leading to the obliteration of the apocrine and eccrine glands. Hong and colleagues<sup>4</sup> and Lee and colleagues<sup>5</sup> have demonstrated the histological changes subsequent to therapy, which includes the obliteration of the apocrine and eccrine glands, leading to fibrosis of the deep dermis.

The effectiveness of the device has been demonstrated recently in a randomised control trial.<sup>6</sup> This article aimed to determine patients' satisfaction with this new treatment modality. In order to achieve this we examined a number of variables, which included the efficacy and speed of response to treatment, the complications of the procedure and the time needed to return to full physical activity after the procedure.

## METHODS

From June 2014 to May 2015, 20 patients (11 male and nine female) underwent treatment with a microwave device for bilateral hyperhidrosis of the armpits. Inclusion criteria included severe hyperhidrosis with ratings three and above, using the hyperhidrosis disease severity scale (HDSS) (Table 1). The HDSS was developed by the International Hyperhidrosis Society as a tool to evaluate the impact of underarm sweating on patients. All patients had failed previous treatments with topical agents.

Patients underwent evaluation with the starch iodine test to determine the treatment area. This was followed by the administration of tumescent anaesthesia using 0.05% lignocaine. The microwave treatment was then administered to the patients on both armpits. The machine emits a constant frequency of 5800 MHz that heats the underlying structures. The energy levels are determined by the length of time for which the device is applied. Level 1 uses a shorter period of application than the longer duration of level 5, which subsequently generates more heat. Most of the patients were treated with level 3 or 4 at the initial visit and level 4 or 5 at the final visit.

Most patients returned for the second treatment at around 3 months after the initial treatment, as per the initial trials.<sup>4,6</sup> Five patients had not received their second treatment at the time of the survey but were nevertheless included in the study.

A retrospective survey on treatment outcomes and complications was conducted through telephone and email questionnaires as well as the analysis of clinical notes. The questions used were standardised so that each patient was asked the same questions, which focused on treatment outcomes and complications (Table 2). The level of sweat reduction was based on the patient's estimation. No patient refused to participate in the study or declined to take the survey.

## RESULTS

The participants' median age was  $30 \pm 5.50$  years with a range of 19–45. The average follow-up time was 5 months

Correspondence: Dr Salvatore Scuderi, Department of Dermatology, Princess Alexander Hospital, 199 Ipswich Road Woolloongabba, Brisbane, Qld 4102, Australia. Email: salvatore.scuderi@gmail.com

Salvatore Scuderi, MBBS, Patricia Manoharan, PhD, Davin Lim, FACD, Shobhan Manoharan, FACD.

Conflict of interest: none.

Submitted 7 October 2015; accepted 28 November 2015.

Abbreviation:

HDSS hyperhidrosis disease severity scale

**Table 1** Hyperhidrosis disease severity scale

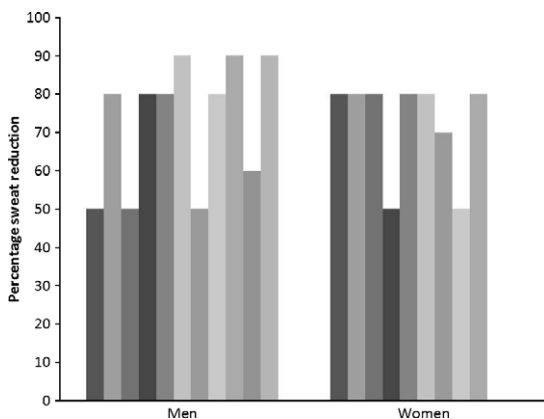
1.	My sweating is never noticeable and never interferes with my daily activities
2.	My sweating is tolerable but sometimes interferes with my daily activities
3.	My sweating is barely tolerable and frequently interferes with my daily activities
4.	My sweating is intolerable and always interferes with my daily activities

**Table 2** Standard questionnaire used in the study

How long ago did you have the microwave treatment?
How many treatments did you have?
Given the hyperhidrosis disease severity scale score outline of 1–4 what would you rate your level of sweating before your treatment?
What is your score now?
What percentage sweat reduction would you estimate resulted after your treatment?
Thinking back to the days and weeks after your treatment, are there any complications or adverse effects of the treatment that you would like to report?
How many days did it take before you were able to resume full physical activity, including strenuous activities such as going to the gym?
Overall, are you satisfied with the microwave treatment for your hyperhidrosis and would you undergo the treatment again?

with a range of 1–12 months. The mean percentage sweat reduction was 72.5% ( $\pm 14.82$ ). Figure 1 shows that both men and women perceived that they experienced significant sweat reduction after the procedure. A comparison was made between those followed up for 3 months or less and those followed up for a period of more than 3 months and up to 12 months (Fig. 2). The average estimated sweat reduction of the short-term follow-up group ( $n = 7$ ) was 74.3%. This was similar to the long-term follow up group ( $n = 15$ ) who averaged 77.7% perceived sweat reduction.

The HDSS severity score of the entire group was compared before and after treatment. The mean HDSS of the

**Figure 1** Percentage reduction in axillary hyperhidrosis for individual men and women.

group pretreatment was 3.75 ( $\pm 0.44$ ) and after treatment it was 1.75 ( $\pm 0.55$ ). There was a mean difference before and after treatment of 2 HDSS points with a 95% confidence interval ranging from 1.85 to 2.15 (two-tailed paired *t*-test done with a *P* value  $< 0.0001$ ).

All patients except for one had an HDSS score of equal to or less than 2 at follow up. The most common short-term side effects were pain (65%), swelling (60%), bruising (15%) and temporary numbness (20%). The pain and swelling was mild and typically lasted 2 weeks. Longer term side-effects included regional hair loss (25%) and nodule formation (25%). Nodule formation lasted up to 4 weeks and hair loss was the only permanent side-effect seen (Fig. 3). The average return to complete physical activity was 8.75 days after their last treatment (Fig. 4). Patients were asked, in retrospect, if they were satisfied and if they would undertake the treatment once again. All patients indicated they would undertake the treatment once again, demonstrating their satisfaction with the outcome.

## DISCUSSION

Our data support the premise that microwave treatment for axillary hyperhidrosis is an effective treatment with significant patient satisfaction. Our results demonstrate a relatively rapid response time, as well as a significant perceived reduction in sweat production. Furthermore, most of our patients were able to return to full physical activity in a relatively short time period. The side-effects found were all relatively minor and short term only. Other studies have identified similar complications, as well as one case of transient motor neuropathy associated with arm weakness.<sup>4</sup>

Injections of botulinum type A toxin have been found to be effective in the treatment of axillary hyperhidrosis. However, the average duration of its effectiveness is only 6–9 months.<sup>2</sup> A 12-month follow up of patients undergoing microwave treatment indicates that the efficacy of this technique is more durable and may be a long-term solution.<sup>4</sup> Permanent treatment modalities have been explored in the literature, including radical surgical excision, excision with liposuction and endoscopic thoracic sympathectomy.<sup>6</sup> Recently a neodymium-doped yttrium aluminium garnet laser used on the skin surface,<sup>7</sup> as well as subdermally,<sup>8</sup> has been demonstrated to reduce axillary hyperhidrosis. While effective, these invasive procedures are associated with long recovery times and leave significant scarring and retraction. Importantly, the rate of compensatory hyperhidrosis found in a patient satisfaction survey after endoscopic thoracic sympathectomy has been as high as 94%.<sup>9</sup> Nonetheless, overall patient satisfaction with endoscopic thoracic sympathectomy was rather high at 88.7% (3-year follow up).<sup>10</sup> New and promising modalities for the treatment of axillary hyperhidrosis include fractionated microneedle radiofrequency treatment<sup>11</sup> and high-intensity micro-focused ultrasound.<sup>12</sup> In terms of medical management, the long-term use of oxybutynin has been evaluated for axillary hyperhidrosis. While it has been shown to be effective, 75.5% of patients suffer from the side-effect of a dry mouth.<sup>2</sup>

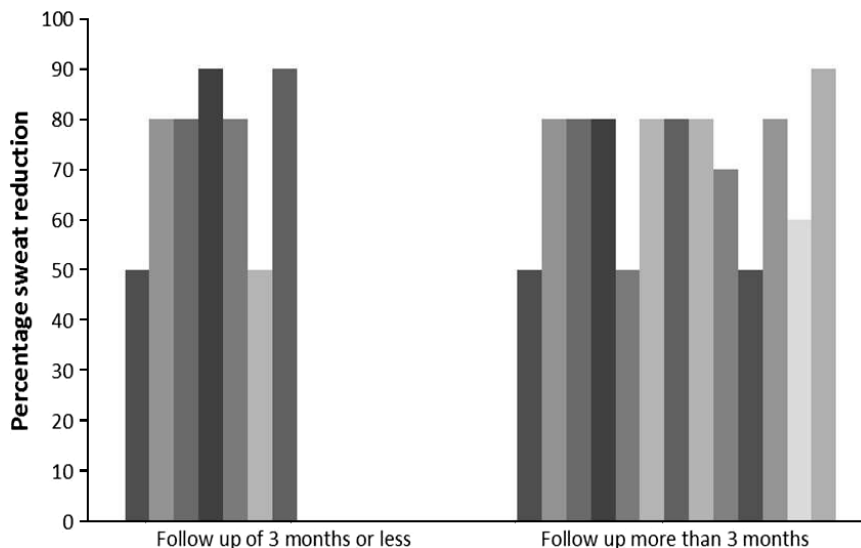


Figure 2 The percentage sweat reduction in individuals in short-term and long-term follow up.

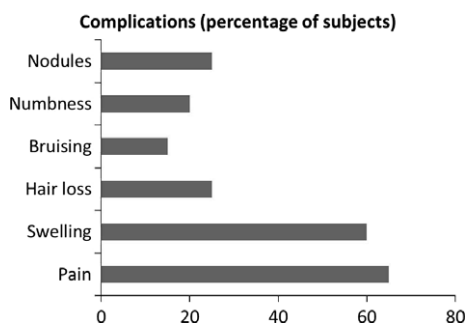


Figure 3 Percentage of subjects experiencing complications from the microwave device.

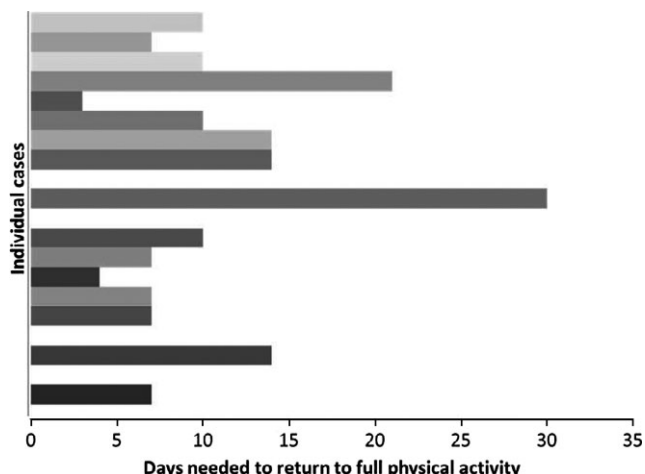


Figure 4 Number of days needed by each patient to return to full physical activity.

Microwave treatment for axillary hyperhidrosis is effective and associated with few side-effects. The effectiveness of the device has been supported by a randomised control

trial with follow up over 12 months. The active arm demonstrated a statistically significant improvement with positive responders defined as those reaching an HDSS score of 2 or less.<sup>6</sup> Furthermore, Hong and colleagues's<sup>4</sup> unblinded study of 51 patients found that 90.3% reached a positive outcome with an HDSS score of 2 or less at a 12 months follow up after the procedure. The modality was also tested on 11 Koreans patients for both axillary hyperhidrosis and osmidrosis, where most patients achieved a drop in the HDSS of at least 2 points (83.3% at a 7-month follow up).<sup>5</sup> Osmidrosis, on the other hand, was evaluated using a subjective scale and 95.8% of participants said the outcome was good or excellent outcome at follow up.

Our research has found that from a patient's point of view, the microwave device is both effective and satisfying in terms of sweat reduction, complication rate and time to return to physical activity. One limitation in our study is the short period of follow up. Furthermore, because it is a retrospective patient-focused survey, the accuracy of the outcomes may be influenced by patients' perception, memory and recall bias. Finally, in order to establish the microwave technique as a permanent management option, further studies with longer follow-up periods are needed.

### CONCLUSION

Axillary hyperhidrosis is a common problem with distressing effects on human interaction and a negative impact on the patient's quality of life. Fortunately, it has been shown to respond well to microwave treatment. While surgical intervention does provide long-term management to the problem, it is invasive and is associated with a high degree of compensatory hyperhidrosis. Non-permanent treatments such as oral medications and injections have unwanted side-effects and are expensive and temporary. The microwave device treatment offers an additional solution to this distressing problem. In this article we have evaluated

patients' satisfaction by examining the response time after treatment, number of days taken to return to normal physical activity and complications. Our results indicate that the microwave device provides an effective, minimally invasive modality with little downtime and high patient satisfaction.

## REFERENCES

1. Henning H. Impact of hyperhidrosis on quality of life and its assessment. *Dermatol. Clin.* 2004; **52**: 467–76.
2. Jacob C. Treatment of hyperhidrosis with microwave technology. *Semin. Cutan. Med. Surg.* 2013; **52**: 2–8.
5. Johnson JE, O'Shaughnessy KF, Kim S. Microwave thermolysis of sweat glands. *Lasers Surg. Med.* 2012; **44**: 20–5.
4. Hong HC, Lupin M, O'Shaughnessy KF. Clinical evaluation of a microwave device for treating axillary hyperhidrosis. *Dermatol. Surg.* 2012; **38**: 728–35.
5. Lee S, Chang K, Suh D *et al.* The efficacy of a microwave device for treating axillary hyperhidrosis and osmidrosis in Asians: a preliminary study. *J. Cosmet. Laser Ther.* 2013; **15**: 255–9.
6. Glaser DA, Coleman WP III, Fan LK *et al.* A randomized, blinded clinical evaluation of a novel microwave device for treating axillary hyperhidrosis: the dermatologic reduction in underarm perspiration study. *Dermatol. Surg.* 2012; **38**: 185–91.
7. Letada PR, Landers JT, Uebelhoer NS *et al.* Treatment of focal axillary hyperhidrosis using a long-pulsed Nd:Yag 1064 nm laser at hair reduction settings. *J. Drugs Dermatol.* 2012; **11**: 59–65.
8. Goldman A, Wollina U. Subdermal Nd-Yag laser for axillary hyperhidrosis. *Dermatol. Surg.* 2008; **34**: 756–62.
9. Chwajol M, Barrenechea IJ, Chakraborty S *et al.* Impact of compensatory hyperhidrosis on patient satisfaction after endoscopic thoracic sympathectomy. *Neurosurgery* 2009; **64**: 511–8.
10. Karamustafaoglu YA, Kuzucuoglu M, Yanik F *et al.* 5-year follow-up after uniportal thoracoscopic sympathectomy for hyperhidrosis: undesirable side effects. *J Laparoendosc. Adv. Surg. Tech. A.* 2014; **24**: 782–5.
11. Fatemi Naeini F, Abtahi-Naeini B, Pourazizi M *et al.* Fractionated microneedle radiofrequency for treatment of primary axillary hyperhidrosis: a sham control study. *Australas. J. Dermatol.* 2014; **56**: 279–84.
12. Nestor MS, Park H. Safety and efficacy of micro-focused ultrasound plus visualization for the treatment of axillary hyperhidrosis. *J. Clin. Aesthet. Dermatol.* 2014; **4**: 14–21.