

## Hypertrophic Scars and Keloids—A Review of Their Pathophysiology, Risk Factors, and Therapeutic Management

DOLORES WOLFRAM, MD,\* ALEXANDAR TZANKOV, MD,† PETRA PÜLZL, MD,\* AND HILDEGUNDE PIZA-KATZER, MD\*

**BACKGROUND** Hypertrophic scars and keloids result from an abnormal fibrous wound healing process in which tissue repair and regeneration-regulating mechanism control is lost. These abnormal fibrous growths present a major therapeutic dilemma and challenge to the plastic surgeon because they are disfiguring and frequently recur.

**OBJECTIVE** To provide updated clinical and experimental information on hypertrophic scars and keloids so that physicians can better understand and properly treat such lesions.

**METHODS** A Medline literature search was performed for relevant publications and for diverse strategies for management of hypertrophic scars and keloids.

**CONCLUSION** The growing understanding of the molecular processes of normal and abnormal wound healing is promising for discovery of novel approaches for the management of hypertrophic scars and keloids. Although optimal treatment of these lesions remains undefined, successful healing can be achieved only with combined multidisciplinary therapeutic regimens.

*The authors have indicated no significant interest with commercial supporters.*

Hypertrophic scars and keloids are a problem that mainly dermatologists and plastic surgeons encounter. Especially in the head and neck region, these lesions are conspicuous and not easy for patients to conceal. Patients typically present with cosmetic concerns, although hypertrophic scars and keloids can also cause pruritus, pain, or pressure.<sup>1</sup> This article reviews various treatment modalities for aberrant wound healing and the updated findings of molecular scar biology.

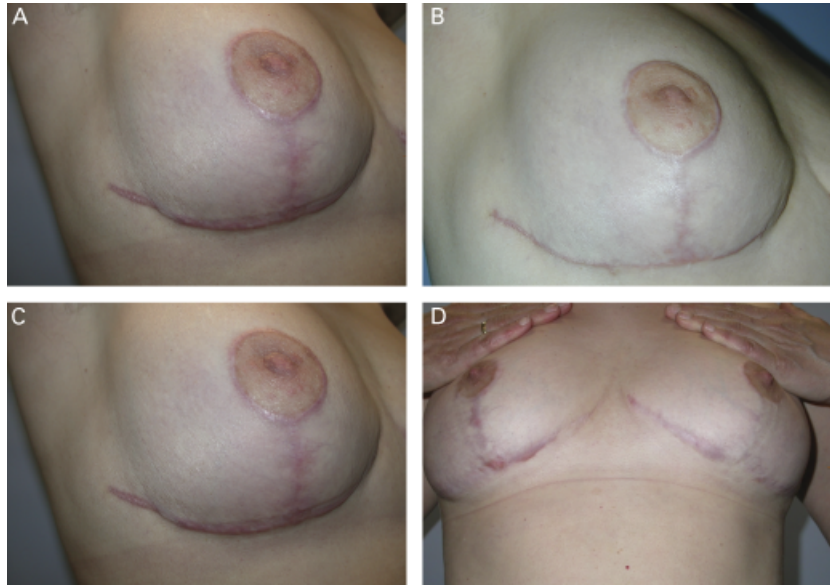
### Hypertrophic Scar Versus Keloid

Hypertrophic scars and keloids are abnormal wound responses in predisposed individuals and represent a connective tissue response to trauma, inflammation, surgery, or burns.<sup>2</sup> The first challenge to scar therapy begins with the simple identification and diagnosis of the problematic abnormal wound healing.<sup>3</sup> Hyper-

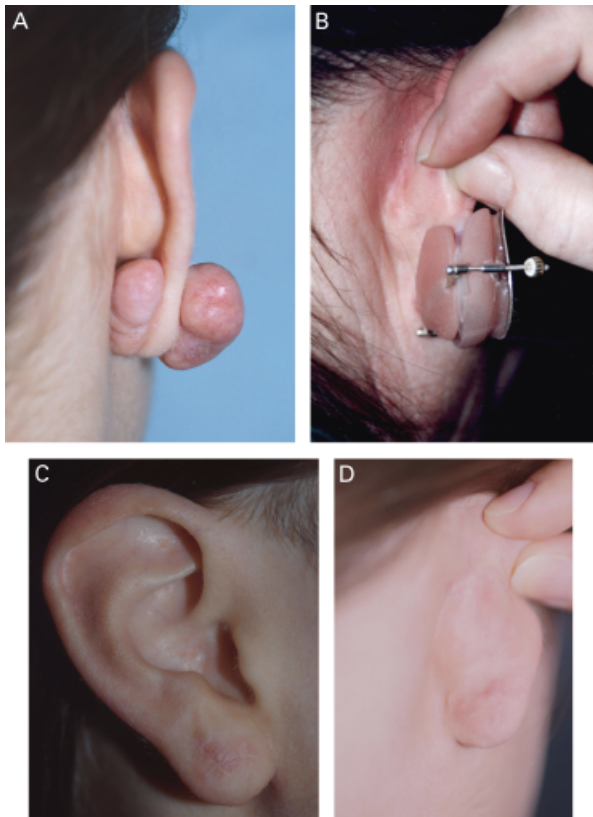
trophic scars are typically raised, red or pink, and sometimes pruritic but do not exceed the margins of the original wound, whereas keloids infiltrate into surrounding normal tissue and rarely regress (Figures 1 and 2). Hypertrophic scars usually subside with time, whereas keloids continue to evolve over time, without a quiescent or regressive phase.<sup>2–5</sup>

Aside from clinical features, histologic characteristics also help distinguish between hypertrophic scars and keloids. Normal skin contains collagen bundles running parallel to the epithelial surface. In hypertrophic scars, the primarily type III collagen bundles are flatter, with the fibers arranged in a wavy pattern but predominantly oriented parallel to the epithelial surface.<sup>6–9</sup> Furthermore, nodular structures in which alpha-smooth muscle actin ( $\alpha$ -SMA)-expressing myofibroblasts, small vessels, and fine collagen fibers are present characterize hypertrophic scars

\*Department of Plastic and Reconstructive Surgery, Innsbruck Medical University, Innsbruck, Austria; †Department of Pathology, Universitätsspital Basel, Basel, Switzerland



**Figure 1.** (A) Hypertrophic scars with intense itching 5 months after reduction mammoplasty. (B) 1 month after scar excision and suturing without resorbable suture. (C) 9 months postoperatively, the scars were hypertrophic again and were treated with corticosteroid injections. (D) Result after five cycles of corticosteroid therapy—25 months after surgery.



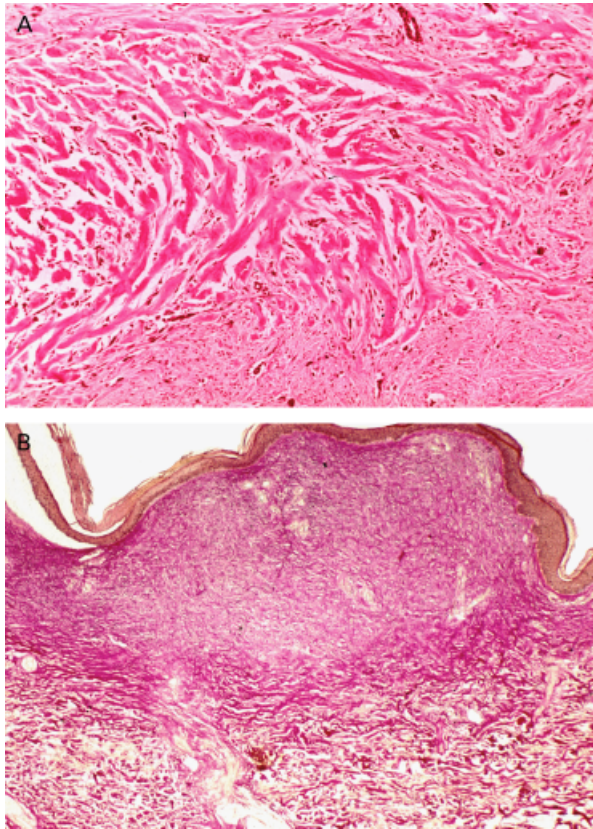
**Figure 2.** (A) Massive keloid formation after ear piercing. (B) Pressure therapy after keloid excision with a pressure clip. (C and D) Results 3 years after successful therapy.

(Figure 3A). In contrast, in keloids, collagen bundles are virtually nonexistent, and the collagen type I and III fibers lie in haphazardly connected loose sheets (Figure 3B) randomly oriented to the epithelial surface.<sup>10,11</sup> Overproduction of fibroblast proteins like transforming growth factor-beta (TGF- $\beta$ ) and platelet-derived growth factor (PDGF) in both abnormal wound responses suggests pathologic persistence of wound healing signals or failure of the appropriate down-regulation of wound-healing cells<sup>12,13</sup> (Table 1).

### Normal Wound-Healing Process

Understanding the normal sequence of wound healing is important in understanding the pathophysiology and treatment of hypertrophic scars and keloids. Normal wound healing occurs in three phases: (1) the inflammatory phase, (2) the proliferative or granulation phase, and (3) the maturation or remodeling phase.

The initial inflammatory phase begins at the time of wounding, when activation of the coagulation cascade causes a release of cytokines that stimulate chemotaxis of unspecific immune cells (e.g., macro-



**Figure 3.** (A) Hypertrophic scar, overview, Van Gieson stain,  $\times 20$ . Note a raised, nodular structure consisting of parallel collagen bundles. (B) Keloid, detail, hematoxylin and eosin stain,  $\times 100$ . Note thick, haphazardly lying, nonoriented collagen bundles.

phages and neutrophils) into the wound for early wound debridement. After 48 to 72 hours, the inflammatory process passes into the proliferative phase, which lasts for 3 to 6 weeks. Fibroblasts are attracted into the wound to synthesize granulation tissue. This granulation tissue is composed of procollagen, elastin, proteoglycans, and hyaluronic acid and forms a structural repair framework to allow vascular ingrowth. Myofibroblasts containing myofibrils ( $\alpha$ -SMA, desmin) are responsible for physiologic wound contraction, and once a wound is closed, the immature scar can move on to the final maturation phase, which can last several months.<sup>13–15</sup>

A multitude of signaling molecules, including growth factors [TGF- $\beta$ , PDGF, vascular endothelial growth factor (VEGF)], mitogen-activated protein (MAP) kinases, matrix metalloproteinases (MMPs), and

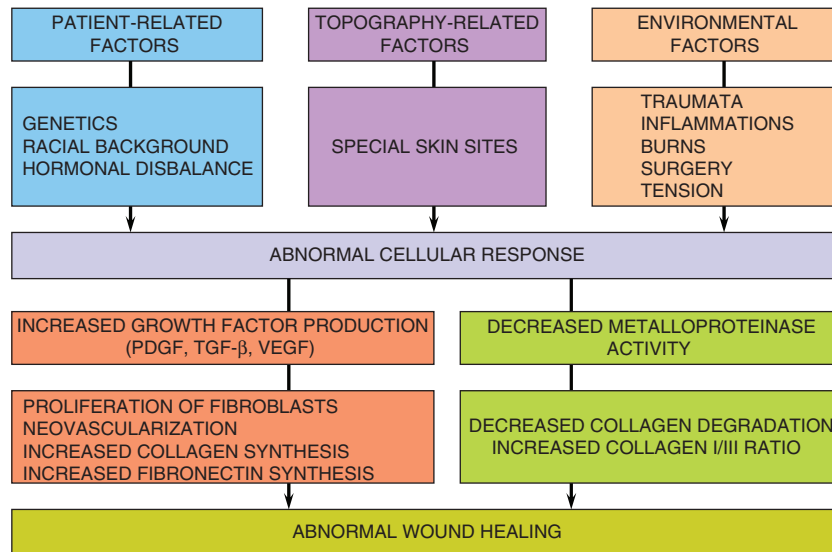
**TABLE 1. Clinical Features of Hypertrophic Scars and Keloids**

<i>Hypertrophic Scars</i>	<i>Keloids</i>
Develop soon after surgery	May develop months after the trauma
Usually improve with time	Rarely improve with time
Remain within the confines of the wound	Spread outside the boundaries of the initial lesion
Occur when scars cross joints or skin creases at a right angle	Occur predominantly on the ear lobe, shoulders, sternal notch, rarely develop across joints
Improve with appropriate surgery	Are often worsened by surgery
Are of frequent incidence	Are of rare incidence
Have no association with skin color	Are associated with dark skin color

tissue inhibitors of metalloproteinases (TIMPs), regulate this complex process of wound healing on the molecular level (Figure 4). The effector molecules that link these regulatory signals and the various phases of wound healing are incompletely understood,<sup>16–19</sup> although it is known that a derailment in this complex wound-healing process contributes to hypertrophic scars and keloid formation.<sup>3</sup>

### Pathophysiology of Hypertrophic Scars and Keloids

In the normal maturation phase, the nodularity and redness of the wound soften and flatten due to ongoing simultaneous collagen synthesis and degradation and the connective tissue elements regress after the third week.<sup>2</sup> In keloids, the collagen synthesis is approximately 20 times as great as that in normal unscarred skin and three times as great as in hypertrophic scars.<sup>20,21</sup> Abergel and colleagues showed that not only is collagen production high in hypertrophic scars and keloids, but the ratio of type I to type III collagen is also high.<sup>22</sup> Friedman and colleagues postulated that, in keloids, the downregulation of type I collagen synthesis is inefficient.<sup>23</sup> This collagen overproduction can be attributed to the stronger proliferating activity of keloid



**Figure 4.** Pathogenesis of abnormal wound healing.

fibroblasts.<sup>24</sup> Aside from high collagen synthesis and proliferation of fibroblasts in keloids, Oliver and colleagues and Babu and colleagues found that keloid-derived fibroblasts show a rate of fibronectin biosynthesis that is as much as four times as high as that of fibroblasts from normal scars and normal dermis.<sup>25,26</sup>

Recent studies investigated the influence of various growth factors in scar and keloid formation. TGF- $\beta$  and PDGF have been shown to play an integral role in the formation of hypertrophic scars and keloids. The majority of cells involved in wound healing express TGF- $\beta$  in an inactive form that strongly promotes the chemotaxis of fibroblasts to the site of injury. Moreover, this growth factor plays a critical role in fibroblast proliferation and collagen production.<sup>27</sup> When wound repair is completed, the activity of TGF- $\beta$  is normally turned off. In keloidal tissue, TGF- $\beta$  is overproduced and poorly regulated through normal autocrine signaling mechanisms. At the same time, keloid fibroblasts have greater numbers of growth factor receptors and respond more intensely to growth factors such as TGF- $\beta$  and PDGF.<sup>15,28</sup> Less synthesis of molecules that promote matrix breakdown (e.g., MMPs) may also explain the lack of scar regression seen in keloids.<sup>13</sup>

Furthermore, disturbed apoptosis mechanisms are discussed in the development of hypertrophic scars and keloids. Messadi and colleagues and Luo and colleagues demonstrated a significantly higher rate of apoptosis in normal skin fibroblasts than in keloidal fibroblasts.<sup>29,30</sup>

### Etiology

Factors that play a major role in keloid development are genetic predisposition and some form of skin trauma.<sup>2</sup> Skin or wound tension has also been implicated as a critical factor in hypertrophic scars and keloids, as have been incisions beyond the relaxed skin tension lines.<sup>31,32</sup> Scars that cross joints or skin creases at a right angle are predisposed to form hypertrophic scars because of the constant tension forces that occur.<sup>33</sup> Although keloids can occur at any age, they tend to develop more readily during and after puberty.<sup>2</sup> Davies explained this fact by stating that younger individuals are more frequently subjected to trauma and their skin is more elastic than the skin of elderly persons.<sup>34</sup> The fact that keloids are 15 times as likely to occur in darker-skinned individuals points to genetic influences.<sup>35</sup> Keloid formation mainly occurs in parts of the body with high concentrations of melanocytes, and it is

rare on the soles and palms. Keloid formation has also been associated with endocrine factors. Menopause also prompts the recession of keloids, whereas women report keloid onset or enlargement during pregnancy.<sup>21,36</sup>

**Prevention and Treatment**

The most important factor in hypertrophic scar and keloid formation is prevention. Avoiding all unnecessary wounds, especially in keloid-prone patients, remains an obvious but imperfect solution.<sup>3</sup> All surgical wounds should be closed with minimal tension, incisions should not cross joint spaces, midchest incisions should be avoided, and incisions should follow skin creases whenever possible.<sup>3,33,37</sup> Especially in head and neck surgery, the esthetic subunits of the face must be considered for incision sites.<sup>38</sup> An atraumatic operation technique should be used, followed by efficient hemostasis, and wound

closure should include eversion of the wound edges. It is also crucial to properly débride contaminated wounds and limit foreign bodies in the form of polyfilamentous sutures.<sup>3</sup> Particularly in the face, subcutaneous sutures should be used only when necessary. Furthermore, wound healing and the esthetic outcome of scar formation can be improved with massage or greasing ointments<sup>38</sup> (Figure 5).

**Surgery for Hypertrophic Scars**

For patients with hypertrophic scars from complicated (e.g., infected) wounds or delayed closure, simple excision is the therapy of choice. Scar revision as a treatment achieves two aims: excision and narrowing of scars as done for wide-spread scars and Z- or W-plasty designed to change the direction of the scar.<sup>2,39</sup> The extension of a reduced distance is the main principle of Z-plasty, and this surgical scar disruption turns the main axis of the scar parallel to

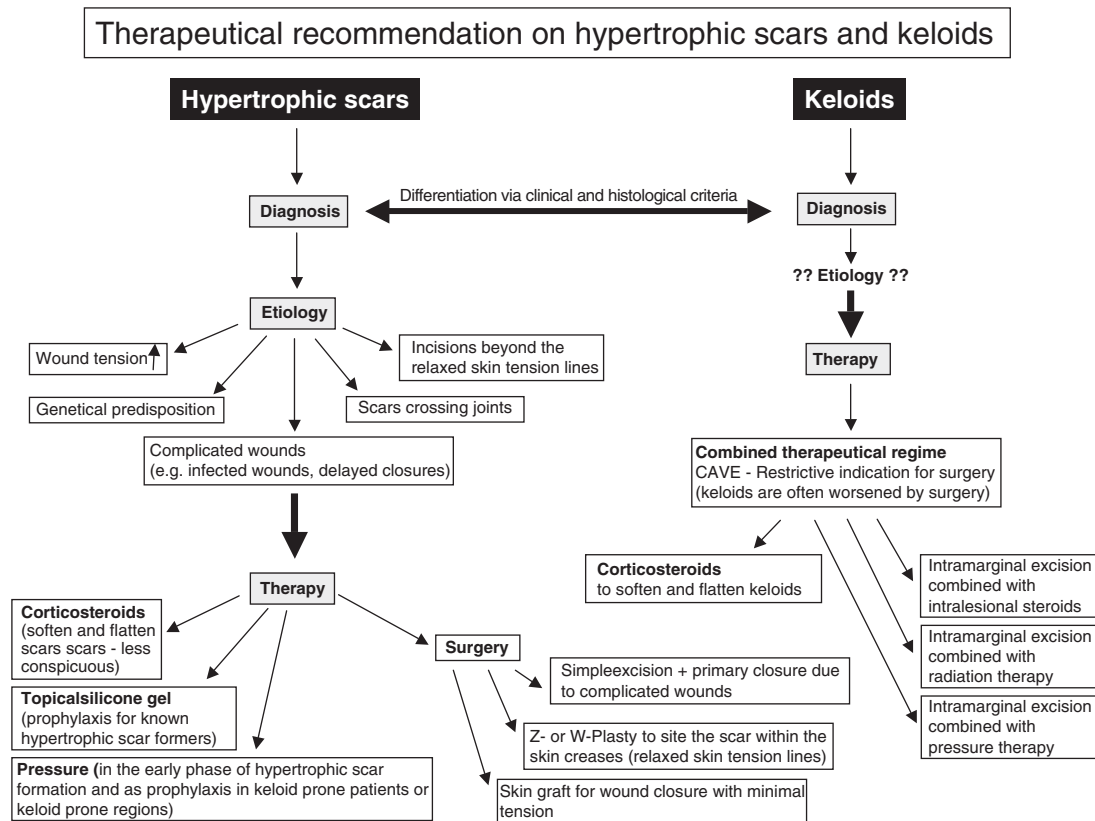


Figure 5. Therapeutic recommendation for hypertrophic scars and keloids.

skin creases.<sup>2,39,40</sup> Z-plasty is ideal in patients with hypertrophic scars crossing joints or wrinkle creases at a right angle, because this technique brings the new scar within the relaxed skin tension lines,<sup>39</sup> which ultimately improves healing. For the correction of facial scars, W-plasty seems to be optimal because every other scar shank can be positioned within the skin creases.<sup>2,39,41</sup> This therapeutic procedure causes a disruption of the scar that makes the lesion less conspicuous. Unfortunately, not all wounds after scar excision can be closed per primam. Especially in facial surgery, autologous skin transplants, namely full-thickness skin transplants or composite fat-skin grafts, are another valuable alternative to achieve wound closure with minimal tension.<sup>42</sup> The preferred donor sites for skin grafts used for facial defects are the retro- and preauricular sites, as well as the neck or the upper lid. From an esthetic point of view, the color match and texture of these near facial regions is superior to those of the upper arm and other donor sites<sup>42</sup> (Figure 1A–D).

### Surgery for Keloids

Simple total excision of a keloid stimulates additional collagen synthesis, thus sometimes prompting quick recurrence of a keloid even larger than the initial one.<sup>43,44</sup> For this reason, intramarginal surgical excision of keloid tissue is recommended in order not to stimulate additional collagen synthesis.<sup>45</sup> Surgical excision of a keloid alone is associated with a high recurrence rate.<sup>46–48</sup> Thus, surgical therapy should be combined with adjuvant treatment such as pressure, corticosteroids, and radiotherapy. Kauh and colleagues demonstrated that surgical excision combined with steroid injection into the wound bed causes down-regulation of type I collagen gene expression without compromising wound healing.<sup>49</sup> If intralesional steroids are used postoperatively, we recommend leaving the sutures 3 to 5 days longer to prevent wound dehiscence. Nevertheless, surgical therapy for the treatment of keloids has been relegated mainly to second-line therapy for lesions unresponsive to steroids or pressure<sup>20</sup> (Figure 2A–D).

### Pressure

The use of pressure to treat keloids was initially described in 1835,<sup>50</sup> although compression therapy was not popularized until the 1970s, when physicians noted that pressure stockings used on lower extremity burns resulted in scars that matured more rapidly, with less erythema and thickness.<sup>51</sup> The compression phenomenon is not well understood, but theories include the following:<sup>50</sup>

- (1) a decrease in blood flow with a resultant decrease in  $\alpha_2$ -macroglobulin and a subsequent increase in collagenase-mediated collagen breakdown, normally inhibited by  $\alpha_2$ -macroglobulin,
- (2) hypoxia leading to fibroblast degeneration and collagen degradation,
- (3) lower levels of chondroitin 4-sulfate, with a subsequent increase in collagen degradation,
- (4) decreased scar hydration, resulting in mast cell stabilization and a subsequent decrease in neovascularization and matrix production.

Histologic examination showed that pressure therapy in hypertrophic scars partly restores the extracellular matrix organization, like that observed in normal scar tissue, and induces the disappearance of  $\alpha$ -SMA-expressing myofibroblasts, probably by apoptosis.<sup>11</sup> Recent studies have investigated presence of epilysin (MMP-28), a proteolytic enzyme expressed by keratinocytes in response to injury, in normal and hypertrophic scars and evaluated the effect of in vitro compression on its expression. Immunohistochemistry revealed a slight protein presence in normotrophic scar keratinocytes and strong positivity in hypertrophic scar keratinocytes, whereas compression therapy induced a significant reduction in this protein in hypertrophic scars.<sup>52</sup> Other experimental studies were able to show that tumor necrosis factor- $\alpha$  (TNF- $\alpha$ ) release, which is significantly enhanced in hypertrophic scars, can be diminished with compression therapy, whereas the apoptosis rate can be strongly increased in hypertrophic scars with pressure.<sup>53</sup>

The part of the face most amenable to the use of pressure dressings is the ear lobe (Figure 2), and pressure clips are in common use for patients with ear lobe keloids.<sup>54,55</sup> Pressure therapy should be started immediately after reepithelialization of the wound, and patients should wear these pressure devices for continuous 8 to 24 hours a day for the first 6 months of scar healing.<sup>2,3,56</sup> The success rate depends largely on patient compliance.

### Topical Silicone Gel

Topical silicone gel sheeting has enjoyed much popularity in the treatment of abnormal scars. First reported in the early 1980s, silicone therapy has recently been marketed for at-home use to improve the appearance of any scar.<sup>3</sup> It is recommended that these silicone sheets be worn at least 12 hours a day for a minimum of 2 months. The mechanism of action is unknown, but it has been suggested that the greater wound hydration achieved using occlusive therapy (silicone and non-silicone based) affects local keratinocytes to alter growth factor secretion and, secondarily, influences fibroblast regulation.<sup>57-59</sup> It is also believed that hydration decreases capillary permeability, inflammatory and mitogenic mediators, and collagen synthesis.<sup>50</sup> In patients who are known to be hypertrophic scar formers, topical silicone gel sheeting has a distinct effect in impeding the formation of abnormal scars in surgical incisions. Application of silicone gel sheets should begin as soon as reepithelialization is finished, and daily application for at least 12 hours is recommended,<sup>54</sup> although the exact duration needed for maximum benefit is unknown and requires further investigation.

### Radiation

Debeurmann and Gougerot first described the use of X-rays for the treatment of keloids in 1906.<sup>60</sup> Later evidence showed that radiation therapy alone is inadequate for the treatment of keloids;<sup>61</sup> therefore, Cosman and colleagues introduced the use of post-excision radiation therapy as an adjunct to surgical excision.<sup>62</sup> The reported efficacy rate varied between

65% and 99% compared with excision alone.<sup>63,64</sup> It is suggested that radiation directly affects fibroblast proliferation by inducing apoptosis. The total dose recommended for the treatment of keloids varies from 15 to 20 Gy fractionated over five to six treatments.<sup>3</sup> The main drawback of radiation therapy, aside from hyperpigmentation, is the risk of radiation-induced malignancy, although only a few cases have been described, and large treatment cohorts with extensive follow-up have provided no evidence to substantiate the risk of carcinogenesis.<sup>65,66</sup> Nevertheless, radiation therapy is contraindicated in children, as well as in areas of high carcinogenic potential, namely the breast and thyroid.

### Laser Therapy

Many laser types, including the carbon dioxide laser and the pulsed dye laser (PDL), have been tested for treatment of hypertrophic scars and keloids, with varied results.<sup>67,68</sup> The carbon dioxide laser, which is commonly used for skin resurfacing, has not been proven to be more effective in treating problem scars than are other methods.<sup>3</sup> The PDL is considered to be the criterion standard for vascular lesions, such as port wine stains, initial hemangiomas, and facial telangiectasias. Additionally, this laser type is often successfully used for non-vascular indications, such as keloids or hypertrophic scars.<sup>69</sup> Currently, the PDL wavelengths 585 and 595 nm are most frequently used for therapeutic purposes. Alster reported an average improvement of 57% after the first treatment and 83% after the second treatment with PDL for hypertrophic surgical and traumatic scars. In addition to a reduction in erythema, flattening, a clear reduction in itching and pain, and optimization of the skin texture have been observed.<sup>70</sup> The entire scar in each patient was exposed to PDL at a wavelength of 585 nm, a pulse duration of 0.45 ms, and a fluence of 6.5 to 7.25 J/cm<sup>2</sup>. Recent biochemical studies suggest that 585-nm PDL treatment alters signaling pathways to favor collagen degradation and fibroblast apoptosis.<sup>71,72</sup> In contrast to the above-cited results, Chan and colleagues failed to show any clinical improvement using PDL

for hypertrophic scars. In 27 hypertrophic scars, one side of each of which was treated (585 nm, 7–8 J/cm<sup>2</sup>, 2.5 ms, 5 mm), the authors documented no superiority of the treated half after three to six treatments regarding thickness and elasticity, although pain and touch sensitivity were far better on the treated side.<sup>73</sup> Several reports have shown a trend toward better clinical improvement using low to moderate fluences,<sup>69</sup> although laser therapy has not shown a clear advantage over cold scalpel excision, especially in keloids.<sup>74,75</sup>

### Corticosteroids

Intralesional corticosteroid injections have become a mainstay in the treatment of hypertrophic scar and keloids, alone or in combination with other therapeutic procedures.<sup>76</sup> Corticosteroid application can soften and flatten keloids but cannot narrow hypertrophic scars or eliminate keloids.<sup>2</sup> Intralesional corticosteroid injection decreases fibroblast proliferation, collagen synthesis, and glycosaminoglycan synthesis and suppresses pro-inflammatory mediators.<sup>40,50</sup> We recommend beginning with direct serial intralesional corticosteroid injections in an already-developing keloid or hypertrophic scar. The most commonly used drug for steroid injection is triamcinolone acetonide (TA) at a dose of 5 to 10 mg/mL, which should be injected with a 25- to 27-gauge needle into the upper dermis of a developing hypertrophic scar<sup>54</sup> every 3 to 6 weeks. Injections are discontinued when the scar is stable, when surgical intervention is indispensable, or if side effects such as tissue atrophy, hypopigmentation or telangiectasia develop.<sup>5</sup> The treatment of preexisting keloids should begin with three monthly, intralesional injections of TA at a dose of 40 mg/mL mixed with equal parts of 2% lidocaine.<sup>33,54</sup> Some authors also recommend the addition of hyaluronidase, which helps to disperse the injection.<sup>32</sup>

Because tissue absorption through intact or sutured skin is poor, the use of topical steroids is indicated only for superficial lesions, such as those occurring from dermabrasion.<sup>77</sup>

## Other Pharmacologic Therapies

### 5-Fluorouracil

Intralesional injection of the pyrimidine analog 5-fluorouracil (5-FU) has been investigated for the regression of keloids and hypertrophic scars. 5-FU targets rapidly proliferating fibroblasts in dermal wounds responsible for excessive collagen production.<sup>27</sup> 5-FU has been shown to be effective in the treatment of hypertrophic scars, whereas studies of intralesional 5-FU application have provided mixed results in keloids.<sup>3</sup> The injection can be painful, and purpura and ulcers have been documented.<sup>39,78</sup> 5-FU can also be combined with corticosteroids; Fitzpatrick was the first to report improved efficacy and less painful injections by mixing corticosteroids (triamcinolone acetonide) with 5-FU.<sup>79</sup> Apikian and Goodman found that the combination of 5-FU with corticosteroids has fewer undesirable side effects than intralesional corticosteroid injection alone.<sup>80</sup> This combined therapy provides also more rapid response.<sup>81</sup>

### Imiquimod 5% Cream

Imiquimod 5% cream, a topical immune response modifier, is approved for the treatment of genital warts, basal cell carcinoma, and actinic keratoses.<sup>82</sup> Imiquimod stimulates interferon  $\alpha$ , a proinflammatory cytokine, which increases collagen breakdown. Additionally, imiquimod alters the expression of apoptosis-associated genes.<sup>83</sup> Therefore, it has been used in an attempt to reduce keloid recurrence after excision. Berman and Kaufman reported positive effects on the recurrence rate of keloids after post-operative application in 12 patients.<sup>84</sup> By contrast, Malhotra and colleagues showed a complete recurrence of presternal keloids after keloid excision and after imiquimod therapy.<sup>85</sup> The role of imiquimod in the prevention of hypertrophic scars is under evaluation.

### Onion Extract

Allium cepa, or onion extract, is found in numerous scar treatment products.<sup>83</sup> This “botanical” ingredi-

ent exhibited antiinflammatory, bacteriostatic, and collagen down-regulatory properties<sup>86</sup> and improves collagen organization in a rabbit ear model,<sup>87</sup> but three major clinical studies in the United States evaluating the effects of onion extract on human wound healing showed no evidence that this extract could be beneficial in improving hypertrophic scars. Products containing onion extract did not improve scar cosmesis or symptomatology any more than a petrolatum-based ointment.<sup>83</sup>

### **Interferons**

Interferons are cytokines secreted by T-helper cells that, apart from other functions, suppress fibrosis. All interferon isoforms ( $\alpha$ ,  $\beta$ ,  $\gamma$ ) have been shown to reduce collagen and extracellular matrix production while increasing collagenase level but have been applied only experimentally and predominantly in small numbers of patients. Furthermore, the use of interferons is also associated with severe side effects, including fever, chills, night sweats, fatigue, myalgia, and headache.<sup>88,89</sup>

### **Immunotherapy**

Immune modulators and antibody therapies are new in the context of problem scars. Commercial drugs like tacrolimus and sirolimus are known to affect cytokine activation, TNF- $\alpha$ , interferons, and interleukins, with wide-ranging effects on inflammation and cell-cycle regulation. Topically used, these drugs may suppress fibroblast activity and increase the apoptosis rate in keloids.<sup>84</sup> Anti-TGF- $\beta$  antibody application use in animal models decreased scar hypertrophy and collagen contraction.<sup>90</sup> Further molecular investigations will yield more specific, probably gene-based, therapies that are designed not only to treat, but also to prevent problem scars.

### **Conclusion**

The development of hypertrophic scars and keloids is a frustrating problem for the patient and the physician. Despite decades of research, the pathophysiology of aberrant wound healing remains

incompletely understood, and the therapeutic interventions for such lesions often give inconsistent and suboptimal results. The appropriate planning of incisions and gentle handling of the tissue is indispensable in keloid prevention. A better understanding of growth factor functions, wound matrix degradation, and immune regulatory processes is beginning to elucidate the complex process of scar formation. These investigations will help to develop more specific therapies for treating and preventing problem scars.

### **References**

1. Segev F, Jaeger-Roshu S, Gefen-Carmi N, Assia EI. Combined mitomycin C application and free flap conjunctival autograft in pterygium surgery. *Cornea* 2003;22:598–603.
2. English RS, Shenefelt PD. Keloids and hypertrophic scars. *Dermatol Surg* 1999;25:631–8.
3. Slemp AE, Kirschner RE. Keloids and scars: a review of keloids and scars, their pathogenesis, risk factors, and management. *Curr Opin Pediatr* 2006;18:396–402.
4. Murray JC. Scars and keloids. *Dermatol Clin* 1993;11:697–707.
5. Nemeth AJ. Keloids and hypertrophic scars. *J Dermatol Surg Oncol* 1993;19:738–46.
6. Linares HA, Larson DL. Elastic tissue and hypertrophic scars. *Burns* 1976;3:407.
7. Calnan JS, Copenhagen HJ. Autotransplantation of keloid in man. *Br J Surg* 1967;54:330–5.
8. Ehrlich HP, Desmouliere A, Diegelmann RF, et al. Morphological and immunochemical differences between keloid and hypertrophic scar. *Am J Pathol* 1994;145:105–13.
9. Blackburn WR, Cosman B. Histologic basis of keloid and hypertrophic scar differentiation. Clinicopathologic correlation. *Arch Pathol* 1966;82:65–71.
10. Grinnell F. Fibroblasts, myofibroblasts, and wound contracture. *J Cell Biol* 1994;124:401–4.
11. Costa AM, Peyrol S, Porto LC, et al. Mechanical forces induce scar remodeling. Study in non-pressure-treated versus pressure-treated hypertrophic scars. *Am J Pathol* 1999;155:1671–9.
12. Diegelmann RF, Cohen IK, McCoy BJ. Growth kinetics and collagen synthesis of normal skin, normal scar and keloid fibroblasts in vitro. *J Cell Physiol* 1979;98:341–6.
13. Niessen FB, Spauwen PH, Schalkwijk J, Kon M. On the nature of hypertrophic scars and keloids: a review. *Plast Reconstr Surg* 1999;104:1435–58.
14. Nicoletis C, Bazin S, Lous ML. Clinical and biochemical features of normal, defective and pathologic scars. *Clin Plast Surg* 1977;4:347–59.

15. Su CW, Alizadeh K, Boddie A, Lee RC. The problem scar. *Clin Plast Surg* 1998;25:451-65.
16. Tuan TL, Nichter LS. The molecular basis of keloid and hypertrophic scar formation. *Mol Med Today* 1998;4:19-24.
17. Bock O, Yu H, Zitron S, et al. Studies of transforming growth factors beta 1-3 and their receptors I and II in fibroblast of keloids and hypertrophic scars. *Acta Dermatol Venereol* 2005; 85:216-20.
18. Stamenkovic I. Extracellular matrix remodelling: the role of matrix metalloproteinases. *J Pathol* 2003;200:448-64.
19. Pearson G, Robinson F, Beers Gibson T, et al. Mitogen-activated protein (MAP) kinase pathways: regulation and physiological functions. *Endocr Rev* 2001;22:153-83.
20. Rockwell WB, Cohen IK, Ehrlich HP. Keloids and hypertrophic scars. A comprehensive review. *Plast Reconstr Surg* 1989;84: 827-37.
21. Cohen IK, Peacock EE Jr. Keloids and hypertrophic scars. In: McCarthy JG (editor). *Plastic Surgery*. Vol. 1. Philadelphia: Saunders. 1990. p. 732-46.
22. Abergel RP, Pizzurro D, Meeker CA, et al. Biochemical composition of the connective tissue in keloids and analysis of collagen metabolism in keloid fibroblast cultures. *J Invest Dermatol* 1985;84:384-90.
23. Friedman DW, Boyd CD, Mackenzie JW, et al. Regulation of collagen gene expression in keloids and hypertrophic scars. *J Surg Res* 1993;55:214-22.
24. Nakaoka H, Miyauchi S, Miki Y. Proliferating activity of dermal fibroblasts in keloids and hypertrophic scars. *Acta Dermatol Venereol* 1995;75:102-4.
25. Oliver N, Babu M, Diegelmann R. Fibronectin gene transcription is enhanced in abnormal wound healing. *J Invest Dermatol* 1992;99:579-86.
26. Babu M, Diegelmann R, Oliver N. Fibronectin is overproduced by keloid fibroblasts during abnormal wound healing. *Mol Cell Biol* 1989;9:1642-50.
27. Chen MA, Davidson TM. Scar management: prevention and treatment strategies. *Curr Opin Otolaryngol Head Neck Surg* 2005;13:242-7.
28. Haisa M, Okochi H, Grotendorst GR. Elevated levels of PDGF alpha receptors in keloid fibroblasts contribute to an enhanced response to PDGF. *J Invest Dermatol* 1994;103:560-3.
29. Messadi DV, Le A, Berg S, et al. Expression of apoptosis-associated genes by human dermal scar fibroblasts. *Wound Repair Regen* 1999;7:511-7.
30. Luo S, Benathan M, Raffoul W, et al. Abnormal balance between proliferation and apoptotic cell death in fibroblasts derived from keloid lesions. *Plast Reconstr Surg* 2001;107:87-96.
31. Stegman SJ, Tromovitch TA, Glogau RG. Treatment of keloids. In: Stegman SJ, editor. *Cosmetic Dermatologic Surgery*. 2nd ed. Chicago: Year Book Medical; 1990. p. 201-6.
32. Stucker FJ, Shaw GY. An approach to management of keloids. *Arch Otolaryngol Head Neck Surg* 1992;118:63-7.
33. Rudolph R. Wide spread scars, hypertrophic scars and keloids. *Clin Plast Surg* 1987;14:253-60.
34. Davies DM. Plastic and reconstructive surgery. Scars, hypertrophic scars and keloids. *Br Med J* 1985;290:1056-8.
35. Alhady SM, Sivanantharajah K. Keloids in various races. A review of 175 cases. *Plast Reconstr Surg* 1969;44:564-6.
36. Moustafa MF, Abdel-Fattah MA, Abdel-Fattah DC. Presumptive evidence of the effect of pregnancy estrogens on keloid growth. *Plast Reconstr Surg* 1975;56:450-3.
37. Lanza JT, Lucente FE, Har-El G. Keloid. *Otolaryngol Head Neck Surg* 1992;106:741-2.
38. Baisch A, Riedel F. Hyperplastic scars and keloids. Part I: basics and prevention. *HNO* 2006;54:893-904.
39. Baisch A, Riedel F. Hyperplastic scars and keloids. Part II: surgical and non-surgical treatment modalities. *HNO* 2006; 54:981-92.
40. Sherris DA, Larrabee WF, Murakami CS. Management of scar contractures, hypertrophic scars, and keloids. *Otolaryngol Clin North Am* 1995;28:1057-68.
41. Borges AF. The W-plasty versus the Z-plasty scar revision. *Plast Reconstr Surg* 1969;44:58-62.
42. Riedel F, Hormann K. Plastic surgery of skin defects in the face. Principles and perspectives. *HNO* 2005;53:1020-36.
43. Datubo-Brown DD. Keloids: a review of the literature. *Br J Plat Surg* 1990;43:70-7.
44. Salasche SJ, Grabski WJ. Keloids of the earlobes: a surgical technique. *J Dermatol Surg Oncol* 1983;9:552-6.
45. Engrav LH, Gottlieb JR, Millard SP, et al. A comparison of intramarginal and extramarginal excision of hypertrophic burn scars. *Plast Reconstr Surg* 1988;81:40-5.
46. Brown LA Jr, Pierce HE. Keloids: scar revision. *J Dermatol Surg Oncol* 1986;12:51-6.
47. Cosman B, Crikelair GF, Ju MC, et al. The surgical treatment of keloids. *Plast Reconstr Surg* 1961;27:335-45.
48. Shaffer JJ, Taylor SC, Cook-Bolden F. Keloidal scars: a review with a critical look at therapeutic options. *J Am Acad Dermatol* 2002;46:63-97.
49. Kauh YC, Rouda S, Mondragon G, et al. Major suppression of pro-alpha1(I) type I collagen gene expression in the dermis after keloid excision and immediate intrawound injection of triamcinolone acetonide. *J Am Acad Dermatol* 1997;37: 586-9.
50. Urioste SS, Arndt KA, Dover JS. Keloids and hypertrophic scars: review and treatment strategies. *Semin Cutan Med Surg* 1999;18:159-71.
51. Linares HA, Larson DL, Willis-Galstaun BA. Historical notes on the use of pressure in the treatment of hypertrophic scars or keloids. *Burns* 1993;19:17-21.
52. Reno F, Sabbatini M, Stella M, et al. Effect of in vitro mechanical compression on Epilysin (matrix metalloproteinase-28) expression in hypertrophic scars. *Wound Repair Regen* 2005;13:255-61.
53. Reno F, Sabbatini M, Lombardi F, et al. In vitro mechanical compression induces apoptosis and regulates cytokines release in hypertrophic scars. *Wound Repair Regen* 2003;11:331-6.

54. Brissett AE, Sherris DA. Scar contractures, hypertrophic scars and keloids. *Facial Plast Surg* 2001;17:263-72.
55. Agrawal K, Panda KN, Arumugam A. An inexpensive self fabricated pressure clip for the ear lobe. *Br J Plast Surg* 1998;51:122-3.
56. Kischer CW, Shetlar MR, Shetlar CL. Alteration of hypertrophic scars induced by mechanical pressure. *Arch Dermatol* 1975;111:60-4.
57. Gold MH. A controlled clinical trial of topical silicone gel sheeting in the treatment of hypertrophic scars and keloids. *J Am Acad Dermatol* 1994;30:506-7.
58. Fulton JE. Silicone gel sheeting for the prevention and management of evolving hypertrophic and keloid scars. *Dermatol Surg* 1995;21:947-51.
59. Chang CC, Kuo YF, Chiu HC, et al. Hydration, not silicone, modulates the effects of keratinocytes on fibroblasts. *J Surg Res* 1995;59:705-11.
60. DeBeurmann R, Gougerot GH. Cheloides des musquescies. *Ann Dermatol Syphilol* 1906;7:151.
61. Borok TL, Bray M, Sinclair I. Role of ionizing irradiation for 393 keloids. *Int J Radiat Oncol Biol Phys* 1988;15:865-70.
62. Cosman B, Crikelair GF, Ju DM, et al. The surgical treatment of keloids. *Plast Reconstr Surg* 1961;27:335-58.
63. Klumpp DI, Murray JC, Anscher M. Keloids treated with excision followed by radiation therapy. *J Am Acad Dermatol* 1994;31:225-31.
64. Kovalie JJ, Perez CA. Radiation therapy following keloidectomy: a 20-year experience. *Int J Radiat Oncol Biol Phys* 1989;17:77-80.
65. van den Brenk HA, Minty CC. Radiation in the management of keloids and hypertrophic scars. *Br J Surg* 1960;47:595-605.
66. Malaker K, Vijayraghavan K, Hodson I, Al Yafi T. Retrospective analysis of treatment of unresectable keloids with primary radiation over 25 years. *Clin Oncol* 2004;16:290-8.
67. Alster TS. Laser treatment of hypertrophic scars, keloids and striae. *Dermatol Clin* 1997;15:419-29.
68. Goldman MP, Fitzpatrick RE. Laser treatment of scars. *Dermatol Surg* 1995;21:685-7.
69. Karsai S, Roos S, Hammes S, Raulin C. Pulsed dye laser: what's new in non-vascular lesions? *J Eur Acad Dermatol Venereol* 2007;21:877-90. Review.
70. Alster TS. Improvement of erythematous and hypertrophic scars by the 585-nm flashlamp-pumped pulsed dye laser. *Ann Plast Surg* 1994;32:186-90.
71. Kuo YR, Wu WS, Jeng SF, et al. Activation of ERK and p38 kinase mediated keloid fibroblast apoptosis after flashlamp pulsed-dye laser treatment. *Lasers Surg Med* 2005;36:31-7.
72. Kuo YR, Wu WS, Jeng SF, et al. Suppressed TGF-beta1 expression is correlated with up-regulation of matrix metalloproteinase-13 in keloid regression after flashlamp pulsed-dye laser treatment. *Lasers Surg Med* 2005;36:38-42.
73. Chan HH, Wong DS, Ho WS, et al. The use of pulsed dye laser for the prevention and treatment of hypertrophic scars in Chinese persons. *Dermatol Surg* 2004;30:987-94.
74. Norris JE. The effect of carbon dioxide laser surgery on the recurrence of keloids. *Plast Reconstr Surg* 1991;87:44-9.
75. Apfelberg DB, Maser MR, White DN, Lash H. Failure of carbon dioxide laser excision of keloids. *Lasers Surg Med* 1989;9:382-8.
76. Golladay ES. Treatment of keloids by single intraoperative perilesional injection of repository steroid. *South Med J* 1988;81:736-8.
77. Goslen JB. The role of steroids in preventing scar formation. In: Thomas JR, Holt GR, editors. *Facial Scars: Incisions, Revisions, and Camouflage*. St. Louis: CV Mosby; 1989. p. 83-97.
78. Gupta S, Kalra A. Efficacy and safety of intralesional 5-fluorouracil in the treatment of keloids. *Dermatology* 2002;204:130-2.
79. Fitzpatrick RE. Treatment of inflamed hypertrophic scars using intralesional 5-FU. *Dermatol Surg* 1999;25:224-32.
80. Apikian M, Goodman G. Intralesional 5-fluorouracil in the treatment of keloid scars. *Australas J Dermatol* 2004;45:140-3.
81. Asilian A, Darougheh A, Shariati F. New combination of triamcinolone, 5-fluorouracil, and pulsed-dye laser for treatment of keloid and hypertrophic scars. *Dermatol Surg* 2006;32:907-15.
82. Berman B, Villa A. Imiquimod 5% cream for keloid management. *Dermatol Surg* 2003;29:1050-1. Review.
83. Zurada JM, Kriegel D, Davis IC. Topical treatments for hypertrophic scars. *J Am Acad Dermatol* 2006;55:1024-31. Review.
84. Berman B, Kaufman J. Pilot study of the effect of postoperative imiquimod 5% cream on the recurrence rate of excised keloids. *J Am Acad Dermatol* 2002;47(4 Suppl):209-11.
85. Malhotra AK, Gupta S, Khaitan BK, Sharma VK. Imiquimod 5% cream for the prevention of recurrence after excision of presternal keloids. *Dermatology* 2007;215:63-5.
86. Augusti KT. Therapeutic values of onion (*Allium cepa* L.) and garlic (*Allium sativum* L.). *Indian J Exp Biol* 1996;34:634-40. Review.
87. Saulis AS, Mogford JH, Mustoe TA. Effect of Mederma on hypertrophic scarring in the rabbit ear model. *Plast Reconstr Surg* 2002;110:177-83; discussion 184-6.
88. Lee JP, Jalili RB, Tredget EE, et al. Antifibrogenic effects of liposome-encapsulated IFN-alpha2b cream on skin wounds in a fibrotic rabbit ear model. *J Interferon Cytokine Res* 2005;25:627-31.
89. Larrabee WF, East CA, Jaffe HS, et al. Intralesional interferon gamma treatment for keloids and hypertrophic scars. *Arch Otolaryngol Head Neck Surg* 1990;116:1159-62.
90. Lu L, Saulis AS, Liu WR, et al. The temporal effects of anti-TGF-beta1,2 and 3 monoclonal antibody on wound healing and hypertrophic scar formation. *J Am Coll Surg* 2005;201:391-7.

---

Address correspondence and reprint requests to: Dolores Wolfram, MD, Department of Plastic and Reconstructive Surgery, Innsbruck Medical University, Anichstrasse 35, A-6020 Innsbruck, Austria, or e-mail: dolores.wolfram@i-med.ac.at